



\*  
No. 3912.115







1904.—No. 13.

DEPARTMENT OF THE INTERIOR.

US BUREAU OF GOVERNMENT LABORATORIES.

---

BIOLOGICAL LABORATORY.

5912.115  
Bull. No. 13

---

A FATAL INFECTION BY A HITHERTO UNDESCRIBED CHROMOGENIC  
BACTERIUM: *BACILLUS AUREUS FOETIDUS*.

---

PUBLISHED BY

By MAXIMILIAN HERZOG, M. D.

OF THE BUREAU

---

MANILA:  
BUREAU OF PUBLIC PRINTING,  
1904.

6813

Handwritten text, possibly a title or header, mostly illegible due to fading.

391-45-2-2  
10. C. 176

1917  
1918  
1919  
1920  
1921  
1922  
1923  
1924  
1925  
1926  
1927  
1928  
1929  
1930  
1931  
1932  
1933  
1934  
1935  
1936  
1937  
1938  
1939  
1940  
1941  
1942  
1943  
1944  
1945  
1946  
1947  
1948  
1949  
1950  
1951  
1952  
1953  
1954  
1955  
1956  
1957  
1958  
1959  
1960  
1961  
1962  
1963  
1964  
1965  
1966  
1967  
1968  
1969  
1970  
1971  
1972  
1973  
1974  
1975  
1976  
1977  
1978  
1979  
1980  
1981  
1982  
1983  
1984  
1985  
1986  
1987  
1988  
1989  
1990  
1991  
1992  
1993  
1994  
1995  
1996  
1997  
1998  
1999  
2000  
2001  
2002  
2003  
2004  
2005  
2006  
2007  
2008  
2009  
2010  
2011  
2012  
2013  
2014  
2015  
2016  
2017  
2018  
2019  
2020  
2021  
2022  
2023  
2024  
2025  
2026  
2027  
2028  
2029  
2030  
2031  
2032  
2033  
2034  
2035  
2036  
2037  
2038  
2039  
2040  
2041  
2042  
2043  
2044  
2045  
2046  
2047  
2048  
2049  
2050  
2051  
2052  
2053  
2054  
2055  
2056  
2057  
2058  
2059  
2060  
2061  
2062  
2063  
2064  
2065  
2066  
2067  
2068  
2069  
2070  
2071  
2072  
2073  
2074  
2075  
2076  
2077  
2078  
2079  
2080  
2081  
2082  
2083  
2084  
2085  
2086  
2087  
2088  
2089  
2090  
2091  
2092  
2093  
2094  
2095  
2096  
2097  
2098  
2099  
2100

## LETTERS OF TRANSMITTAL.

---

OFFICE OF THE SUPERINTENDENT OF LABORATORIES,

*Manila, April 6, 1904.*

SIR: I have the honor to transmit herewith a report on "A Fatal Infection by a Hitherto Undescribed Chromogenic Bacterium: Bacillus Aureus Fœtidus," by Dr. Maximilian Herzog, Pathologist of the Biological Laboratory.

I am, very respectfully,

PAUL C. FREER,

*Superintendent of Government Laboratories.*

HON. DEAN C. WORCESTER,

*Secretary of the Interior, Manila, P. I.*

---

BIOLOGICAL LABORATORY,

*Manila, P. I., March 23, 1904.*

SIR: I have the honor to transmit herewith and to recommend for publication a report on "A Fatal Infection by a Hitherto Undescribed Chromogenic Bacterium: Bacillus Aureus Fœtidus," by Dr. Maximilian Herzog, Pathologist Biological Laboratory.

Very respectfully,

RICHARD P. STRONG,

*Director Biological Laboratory.*

DR. PAUL C. FREER,

*Superintendent of Government Laboratories, Manila, P. I.*





## ILLUSTRATIONS.

---

- FIGURE 1. Agar tube, twenty-four hours' growth.
2. Litmus lactose agar tube, twenty-four hours' growth.
  3. Agar plate, twenty-four hours' growth.
  4. I, Glycerine agar tube, twenty-four hours' growth; II, Lactose agar tube twenty-four hours' growth; III, Glycerine agar tube, two days' growth, anaerobic; IV, Salt agar tube, twenty-four hours' growth.
  5. V, Litmus lactose agar tube, twenty-four hours' growth; VI, Litmus milk tube, several days' growth; VII, Twenty per cent gelatine tube, twenty-four hours' growth; VIII, Potato tube, three days' growth.
  6. Microphotograph of a cover-glass preparation from an agar culture twenty-four hours old. Stained with dilute carbol-fuchsin. Zeiss Achromatic homogenous oil immersion one-twelfth of an inch, compensation ocular No. 8. Length of bellows, thirty-four centimeters.
  7. Microphotograph of an interstitial inflammatory focus in the kidney, showing a small mass of bacilli. Magnification same as in fig. 6.
  8. Microphotograph of an interlobular inflammatory, periphlebitic focus in the liver. Zeiss objective A. A., Compensation ocular No. 8.
  9. Microphotograph of a degenerated glomerulus, almost complete fibrosis. Magnification same as in Fig. 8.



Digitized by the Internet Archive  
in 2011 with funding from  
Boston Public Library




FIG. 4.—I, Glycerine-agar tube, twenty-four hours' growth; II, Lactose-agar tube, twenty-four hours' growth; III, Glycerine-agar tube, two days' growth, anaerobic; IV, Salt-agar tube, twenty-four hours' growth.






FIG. 5.—V, Litmus-lactose-agar tube, twenty-four hours' growth; VI, Litmus-milk tube, several days' growth; VII, Twenty per cent gelatine tube, twenty-four hours' growth; VIII, Potato tube, three days' growth.



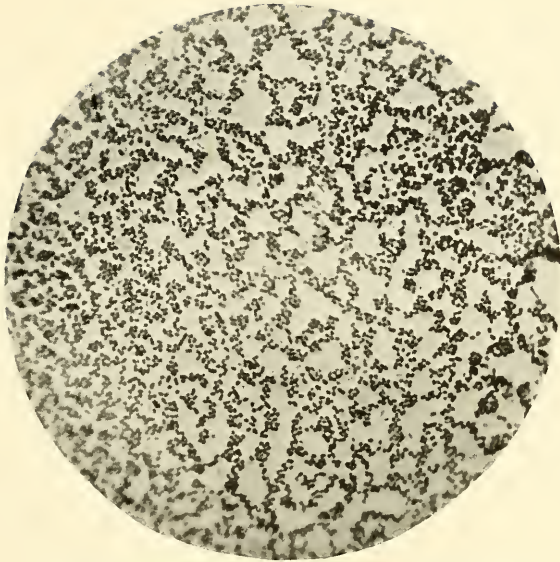


FIG. 6.—Microphotograph of a cover-glass preparation from an agar culture twenty-four hours old. Stained with dilute carbol-fuchsin. Zeiss Apochromatic homogenous oil immersion one-twelfth of an inch, compensation ocular No. 8. Length of bellows, 34 centimeters.

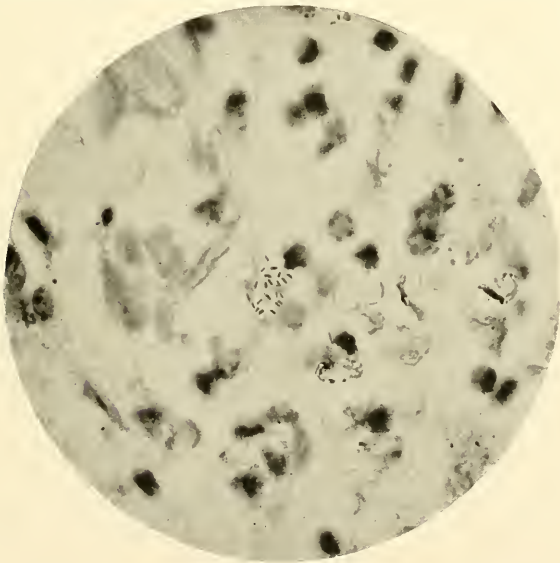


FIG. 7.—Microphotograph of an interstitial inflammatory focus in the kidney, showing a small mass of the bacilli. Magnification same as in fig. 6.





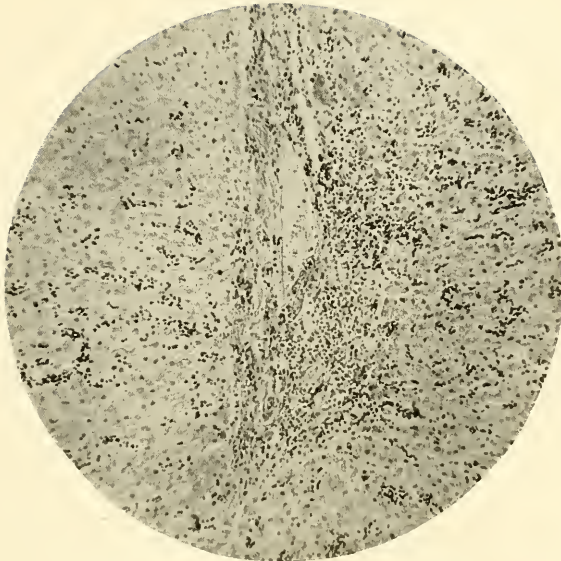

FIG. 8.—Microphotograph of an interlobular inflammatory periphlebitic focus in the liver. Zeiss objective A. A. compensation ocular No. 8.

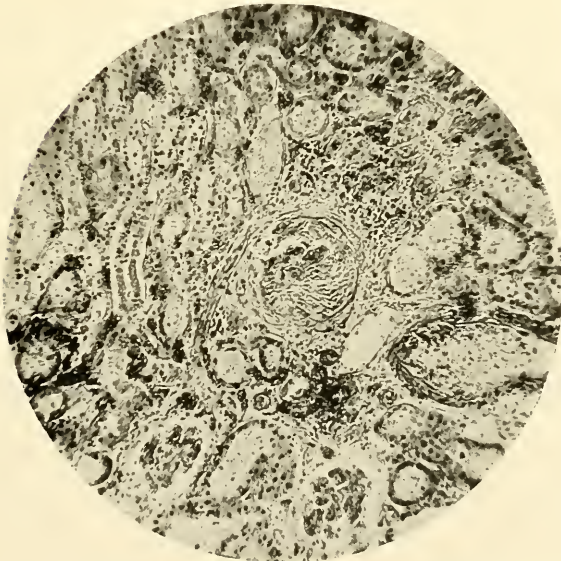

FIG. 9.—Microphotograph of a degenerated glomerulus, almost complete fibrosis. Magnification same as in fig. 8.



## A FATAL INFECTION BY A HITHERTO UNDESCRIBED CHROMOGENIC BACTERIUM: BACILLUS AUREUS FÆTIDUS.

By MAXIMILIAN HERZOG, M. D., *Pathologist, Biological Laboratory.*

The fauna and flora of the Tropics being in general different from those of the more temperate latitudes, in genera as well as in species, we may also reasonably expect this observation to hold good with reference to the very lowest forms of life—bacteria and protozoa—however, without being unmindful of the fact that certain families and even species are distributed over an enormous territory and under the most varied conditions of life.

We can hardly expect to find that bacteria and protozoa, which are strict parasites of widely distributed races, are limited in area, unless it be that they depend in certain stages of their life cycle upon an intermediate host, itself confined to certain regions. To cite an example: The tubercle bacillus is practically found wherever, like the human being, an easily susceptible host of this strict parasite dwells. The *Hæmamoeba malariae*, likewise a parasite of man, is not so widely distributed, because it depends for its spreading upon an intermediate host, the anopheles, the distribution of which is not identical with that of man.

The *a priori* deduction that in the Tropics we will find certain bacteria and protozoa peculiar to this zone will therefore be limited to those bacteria and protozoa which are either strictly saprophytic or parasitic in certain hosts, confined to the Tropics themselves, or which only occasionally and under particularly favorable circumstances lead a parasitic life.

The observation to be recorded in this paper refers to a case of fatal human infection by a hitherto undescribed bacterium, which is evidently not very pathogenic under ordinary conditions and probably, as a rule, is a harmless saprophyte, but which, as in this instance, under circumstances especially favorable, may become parasitic and may lead to a fatal issue. Examples of this type are of course not unknown in clinical medicine. The colon bacillus,

usually a harmless saprophyte, living in the intestinal contents, occasionally invades the juices and tissues of the human body and leads to acute or chronic fatal infections.

The case to be reported is as follows:

On the 19th of February, 1904, the body of D. L., a Filipino, 40 years of age, was sent to the morgue at San Lazaro. No more was known about the case than that the person died rather suddenly, the suspected cause of death being plague. There was an open wound on the right leg and a marked swelling of the inguinal glands of the right side. The post-mortem examination was made eight hours after death. Briefly the findings were as follows:

The body was that of a well-developed man of about 40 to 45 years of age. Post-mortem rigidity was well marked. Post-mortem lividity was extensive on dependent parts of the body and extending somewhat toward the sides of the neck and thorax. There was a swelling of the size of a hazelnut in the right inguinal region. The swollen area was firm and elastic. There was no fluctuation and no edema in the neighborhood. The skin was perfectly intact. There was no difference in color over this area and the surrounding tissues. In the right popliteal space there was an open ulcerated surface 5 by  $1\frac{1}{2}$  centimeters in size, the long diameter being in the long axis of the limb. The ulceration was several millimeters deep, had very sharp, somewhat raised edges, and was covered with a small amount of sero-fibrinous exudate, which became visible after the removal of iodoform, which had been dusted freely on the wound. The open surface was covered with small granulations. The whole condition of the ulcer suggested that the surface had recently been curetted and its edges trimmed. The integument did not show any lesions other than the ulcer described.

On opening the body cavities it was found that the serous membranes were shining and transparent. There was a very small amount of the usual serous fluid in the thoracic and abdominal cavities. It may be stated here that no hemorrhagic spots, petechiæ, or ecchymoses were found anywhere. The pericardium and heart appeared normal. The large vessels were also normal. The lungs were very slightly hyperemic, otherwise normal. Bronchi, trachea, and larynx were normal. Epiglottis was slightly injected. The spleen was normal in size, consistency, and color. The trabeculæ were a little more marked than usual.

The kidneys showed a very marked injection. They were of a deep pinkish-purple hue. The capsules were smooth, even, and transparent and peeled off easily. After removal of the capsule the surface appeared finely granular, but the granular elevations were very faint. The glomeruli appeared strongly injected and were surrounded by a much paler, somewhat grayish-white tissue. On section the glomeruli stood out as deeply injected points, while the deeply injected vessels alternated with somewhat dull, grayish-white tubules. The pyramids were likewise of a deep pinkish-purple color. Relation between cortex and medulla was normal. The mucous membrane of the pelvis was smooth and shining. There was a very small amount of turbid urine in the pelvis. The suprarenals were normal.

The liver was normal in size and rather firm in consistency. The capsule on the whole was smooth and transparent. However, on the upper surface there were seen a few small, irregular, dull, slightly raised perihepatic areas. The surface was here and there slightly uneven and finely though very superficially granular. The color was a pinkish, grayish yellow. On section the color was somewhat deeper and brownish, but otherwise of the same hue as when seen through the capsule. The centers of the lobules were rather grayish white. The veins contained a large amount of dark purplish blood.

The gall bladder was normal and contained a moderate amount of turbid, greenish-yellow bile. The mucous membrane was smooth. There were no stones. The pancreas was perhaps somewhat firmer in consistency than usual, otherwise normal.

Stomach and small intestines: The mucosa was very slightly congested, otherwise normal. The large intestine was normal. The appendix was normal.

Lymph glands: Three of the inguinal glands of the right side were found to be markedly hypertrophic. They were not measured, but appeared to be enlarged to twice their normal size in all their diameters. On the left side they were very slightly enlarged. The markedly hypertrophic glands of the right side were quite firm in consistency, not injected, and rather pale. The cervical glands were slightly enlarged and very moderately congested.

Smears from the organs showed a small number of what appeared to be a small diplococcus or diplobacillus. No organisms showing the characteristic morphology and staining properties of the plague bacillus were found. It was therefore decided that the



case was not one of plague infection. This decision was reached shortly after the post-mortem examination, as it was necessary to determine at once the course to be taken in regard to the disposition of the body and the house from which it came.

The anatomical diagnosis of the post-mortem findings was as follows:

Passive congestion of the kidneys. Passive congestion of the liver. Acute interstitial hepatitis. Hypertrophy of the inguinal glands. Slight hypertrophy and slight congestion of the cervical glands.

*Cause of death.*—Remote; iodoform poisoning (?). Immediate; terminal diplococcus infection.

During the post-mortem examination glycerine agar tubes were inoculated with the usual precautions. The tubes were examined after two days with the following results :

Two tubes inoculated from the liver contained pure cultures of a short, small bacillus, which had produced a golden-yellow pigment.

One tube from the heart's blood developed the same organism, but it was, as shown on the third day, contaminated.

One tube inoculated from the spleen remained permanently sterile. None of the tubes developed the plague bacillus.

Before proceeding to a more detailed description of the organism isolated, it may here be stated that inquiries were made as to the history of the case and as to the possibility of iodoform poisoning. As is usual with the lower class of Filipinos, only a very fragmentary, unsatisfactory history could be obtained. Dr. Christensen, health inspector of the district from which the body was sent in for a post-mortem examination and diagnosis, had never seen the man alive, but learned that he had not been perfectly well for about four months, that he had an open wound on his leg, and that iodoform had been used freely on it for about eight days. No history of any symptoms of iodoform poisoning, such as mental depression, hallucinations, delirium, etc., could be obtained. While the bacteriologic and histologic examination of the case was in progress the liver was examined for iodine in the Chemical Laboratory, with negative results.

#### DESCRIPTION OF THE BACILLUS ISOLATED.

*Morphology.*—Short bacilli with rounded ends, varying much in size. They are from 0.6 to 2 microns long; on an average 1.4

microns. The larger individuals of two microns are rather scarce. In thickness the bacilli vary from 0.55 to 0.8 micron. They are generally about 0.7 micron thick. The proportion of the length to the thickness is usually 2:1. The organism presents itself frequently as a diplobacillus. A large number are short, making them look like diplococci. Occasionally small individuals are found, not materially larger than 0.5 micron and almost spherical, so that it is hard to distinguish them from true diplococci. The bacillus possesses a capsule of moderate size, which can be demonstrated by Muir's method. It does not form long chains, even groups of four in a chain being but rarely seen. Spore formation is not observed. It is not motile, but shows a lively molecular motion in hanging drop preparations.

*Staining properties.*—The bacillus is readily stained by the watery aniline stains and easily overstained by the more intense solutions (carbol-fuchsin, carbol-thionin). When properly treated not all of the bacilli take the stain uniformly, but in some cases the latter acts in such manner as to leave an unstained space in the center. It is not demonstrable that this polar staining is due to the presence of Ernst-Babes's polar granules, because Neiser's methylene-blue-Bismark-brown does not satisfactorily show any such granules, although there appears to be a slight tendency to take up some of the stain at the poles of the bacillus. When properly treated the organism somewhat, though rather remotely, resembles the short type of the pseudodiphtheria bacillus. A certain resemblance also exists between it and the bacillus of plague, though the similarity is not great. Gram's method decolorizes the bacillus. No flagellæ are demonstrable.

*Cultural peculiarities.*—The organism on all solid media which have been tried produces an intense golden-yellow pigment, which is practically identical in color with that formed by the *Staphylococcus pyogenes aureus*. Distinct colonies in 20 per cent gelatine plates are quite difficult to obtain, because the organism liquefies the media with great rapidity. Twenty per cent gelatine stab cultures after twenty-four hours to a great extent become fluid. The liquefaction comprises the entire extent of the upper strata. There is some growth in the depth along the line of the stab, but not much. The liquefied gelatine is very cloudy, and after twenty-four hours a dense scum is formed on its surface. Individual colonies are best studied on agar plates. On agar and glycerine

agar the organism forms a moist, raised, golden-yellow growth after twenty-four hours. The individual colonies are more or less round and likewise moist and raised, with a somewhat undulating surface. The margins are smooth. In spreading, the colonies become confluent. The development on glucose agar is identical with that on ordinary agar. No gas formation occurs. On 3 per cent salt agar the growth is possibly a little slower, although not very much so. The bacillus raised on this medium stains as usual; the involution forms so characteristic in the case of the plague bacillus are never seen. On lactose agar the growth is similar to that on plain agar. There is no gas formation. The development is more rapid on the surface than in the depth of the stab, but it also occurs there, although at a much slower rate. On lactose litmus agar the color begins to turn after twenty-four hours and is quite distinctly red after forty-eight hours. Bouillon after twenty-four hours is strongly clouded, and a scum has been formed on the surface after forty-eight hours. On potatoes a very typical luxuriant growth is observed after twenty-four hours. Litmus milk is slightly reddened after twenty-four hours and strongly so after forty-eight. Coagulation takes place only at the end of several days. The organism develops typically under anaerobic conditions in either a nitrogen or a hydrogen atmosphere. All cultures whether aerobic or anaerobic have a very fetid, cheesy, and somewhat cadaverous smell.

The thermal death point of the organism was determined to be 62° C. An exposure of ten minutes at this temperature destroyed all the bacilli, while 61° C. acting for ten minutes left a number alive.

The name "*Bacillus aureus foetidus*" selected for this micro-organism emphasizes two of its prominent characters, its chromogenic and malodorous properties.

No chromogenic bacterium described in Sternberg's Manual of Bacteriology, Flügge's *Die Mikroorganismen*, Migula's *System der Bakterien*, or the last volumes of the *Centralblatt für Bakteriologie* is identical with the bacillus described in this paper.

#### HISTO-PATHOLOGY.

Pieces of tissue taken at the post-mortem table were at once placed in Zenker's solution. They were subsequently embedded in paraffine and stained with hematoxylin-eosin, eosin-alkaline-



methylene-blue, and by Gram's method. The microscopic examination demonstrates the following tissue changes:

*Liver.*—The boundaries of the lobules are well marked, since the interlobular veins are surrounded by an inflammatory infiltration, the latter in general having the character of a periphlebitic cellular exudate. In a fair number of places this inflammatory process must have been going on for some time, since here the interlobular tissues show a number of fusiform connective tissue cells and fibers. When examined with oil-immersion magnification it is seen that the cellular exudate consists mainly of small round cells of the lymphoid type: here and there a plasma cell is seen. These plasma cells are of the ordinary type with a more or less square or irregular protoplasmic body, deeply staining with methylene blue and with an excentrically situated vesicular nucleus, poor in chromatin. The cellular exudate also shows fusiform cells of the type of fibroblasts, while a number of the small round cells show karyokinetic figures, demonstrating that a lively proliferation has been going on in the inflammatory foci. The latter exhibit a considerable number of very small bacilli found in irregular groups, in groups of two, and in small chains. This micro-organism does not generally stain very well, even with methylene blue. Some, however, keep the dye fairly well.

The liver cells show distinctly noticeable, though not very advanced, degrees of fatty degeneration. This degenerative process is perhaps most marked in the center of the lobules, though it is not confined to the central zone but may be quite diffusely distributed in some areas. The liver capillaries are distended with blood. The capsule of the liver in places shows some thickening. Where this condition prevails we find an interlobular inflammatory focus in the neighborhood of the capsule.

*Kidneys.*—The majority of the glomeruli appear normal; some, however, show an increase in the nuclei of the endothelial lining of the glomerular capillaries, while in others there is a more or less marked thickening of the capsules of Bowman. We also see beginning fibrosis in the interior of the tufts. In a number of the latter the fibrosis is well advanced, and we have a complete obliteration of the capillaries. In the neighborhood of the glomeruli, which show more or less advanced changes, and between the convoluted tubules there are seen inflammatory foci, which consist mostly of small round cells of the lymphoid type. However, there

are also present some plasma cells and plasma "mast cells," and a considerable number of eosinophilic polynuclears. These foci likewise show the small, generally poorly stained bacilli. The epithelial cells lining the uriniferous tubules show cloudy swelling or vacuolation with loss of the nucleus quite extensively. Most tubules contain a granular material; some contain hyaline casts. The renal blood vessels are all distended with blood.

Neither the liver nor the kidneys show any areas of marked or extensive coagulation necrosis nor are areas of blood extravasation encountered, though both the kidneys and the liver show highly engorged capillaries.

*Lymph glands.*—The inguinal lymph nodes show a marked increase in fibrous connective tissue. This increase is noticeable in the capsule, in the trabeculae and around the individual blood vessels. However, the follicles themselves show no marked fibroid changes, and the differentiation between the peripheral zone and the proliferating center of Fleming is well preserved. The lymphoid cells are of the usual character. Karyokinetic figures are here and there seen in the proliferating center of the follicles. The mitoses, however, are not very numerous. Occasionally an eosinophilic polynuclear is encountered. Plasma cells and plasma "mast cells" are also seen. Bacilli like those found in the liver and kidneys are encountered, nowhere in large groups or over large continuous areas, but only as a few isolated individuals here and there forming little groups among the cells. The blood vessels of the lymph nodes are generally well filled. Hemorrhagic areas of extravasated blood are not found.

No histologic changes are found in the pulmonary tissue. The pancreas is normal except in certain portions, where there is seen a minor degree of increase in the interlobular connective tissue.

The myocardium shows fragmentation of a marked degree, the diastases between the fragments not being very large.

A moderate number of cells exhibit a deposit of brown granules in the perinuclear zone. More or less all cells show a very fine, dust-like vacuolization and a somewhat indistinct, hazy striation.

#### ANIMAL EXPERIMENTS.

On February 26, 1904, at 9 a. m., a small monkey (*Macacus philippinensis*) was given an intraperitoneal injection of 2 to 3 c. c. of

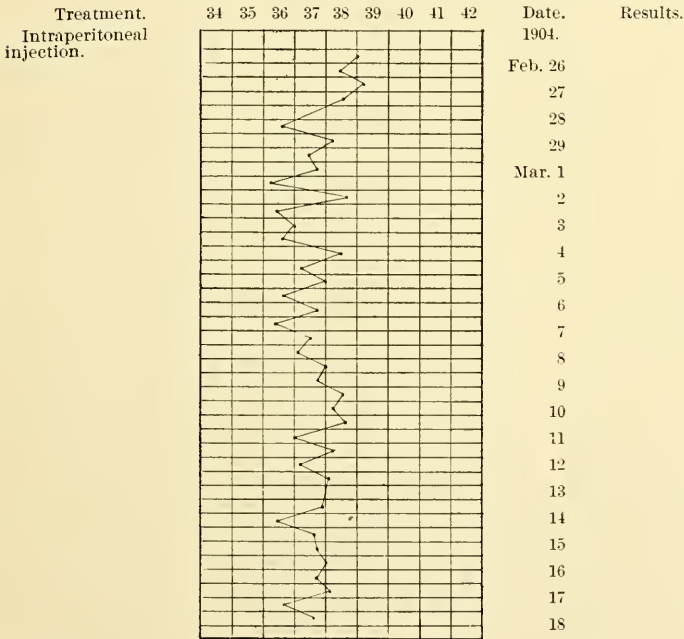
a twenty-four hours' bouillon culture of the bacillus. There was only a very slight reaction, as seen from the temperature chart, and the animal was well at the end of one month. (See Chart No. 1.)

On March 1, 1904, at noon, a good-sized, full-grown rabbit was given an intraperitoneal injection of 2 to 3 c. c. of an emulsion of a two days' agar culture in sterile water. The result was the same as in the case of the monkey. (See Chart No. 2.)

CHART No. 1.

*Monkey No. 558, February 26, 1904.*

[Weight, small; age, young; sex, female; inoculation, 2 to 3 c. c.; history, twenty-four hours' bouillon culture of bacillus aureus foetidus. Intraperitoneal.]



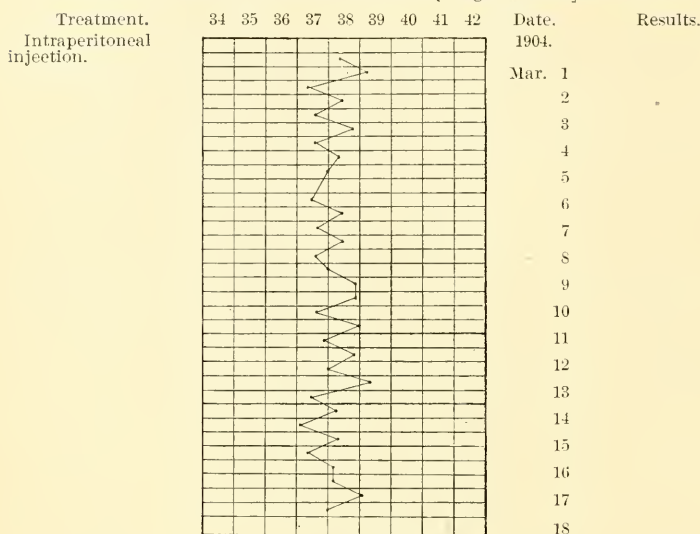
A similarly negative result was obtained with a half-grown wild gray rat inoculated subcutaneously with a platinum loop of a fresh agar growth.

As appears clearly from these animal experiments the bacillus aureus foetidus is not highly pathogenic, and in a single inoculation did not have a tendency to become parasitic.

## CHART No. 2.

*Rabbit No. 561, March 1, 1904.*

[Age, adult; sex, female; color, white; inoculation, 2 to 3 c. c.; history, emulsion of bacillus aureus foetidus from two days' agar culture.]



## CONCLUSIONS.

Bacillus aureus foetidus, the bacterium described in this paper, has, as appears beyond doubt, been the cause of death in the case herein reported. Experiments showed that the bacillus is not a highly pathogenic micro-organism, because single inoculations of moderate doses brought about only a very slight reaction in the animals experimented upon. Perhaps inoculations repeated during a longer period might bring about a more serious result.

It is very probable that bacillus aureus foetidus is ordinarily a saprophyte. In the case reported it may simply have lived for some time in the necrotic tissues of a neglected ulcer and may have slowly become modified in these environments until it finally gained entrance into the tissues of the patient. From the lymphatic system it entered the blood current, reached the liver and kidneys, and led to subacute and somewhat chronic interstitial fibroid processes and parenchymatous degeneration.

As shown by the microscopic examination, beginning interstitial and marked parenchymatous nephritis, as well as early, brown atrophy and fatty degeneration of the myocardium, must be added to the anatomical diagnosis made at the post-mortem table.





BOSTON PUBLIC LIBRARY



3 9999 06724 919 1



